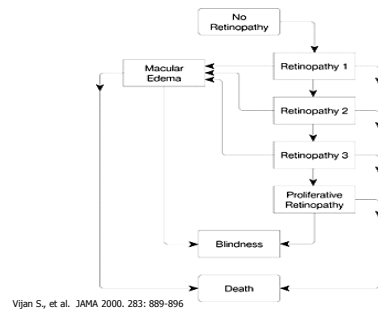


Comanagement of retinal disease

Leo Semes, OD

Diabetic Retinopathy Continuum – All Roads Lead to ME – the greatest cause of vision loss in diabetics



Vijan S., et al. JAMA 2000. 283: 889-896

3

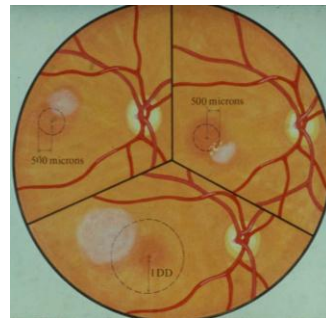
Clinically Significant Macular Edema (CSME)

CSME definitions

- Thickening of the retina \leq 500 microns (1/3 DD) from the center of the macula
- H,E with thickening of the adjacent retina \leq 500 microns (1/3 DD) from the center of the macula
- Any zone of retinal thickening $>$ 1 DA in size \leq 1 DD from the center of the macula

4

Clinically Significant Macular Edema



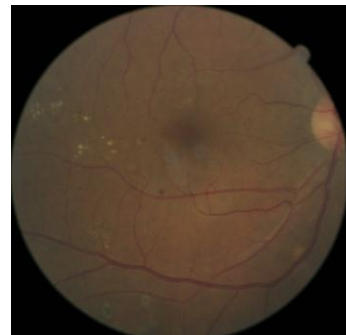5

Diabetic Retinopathy – Macular Edema Summary

- Retinal thickening = fluid accumulation
 - Best visualized CLINICALLY at stereoscopic slit-lamp examination
- A clue to presence is *exudates* (lipid deposits) at the border of the edema
- *Edema is transient* but *exudates beneath the fovea are associated with permanent vision loss*

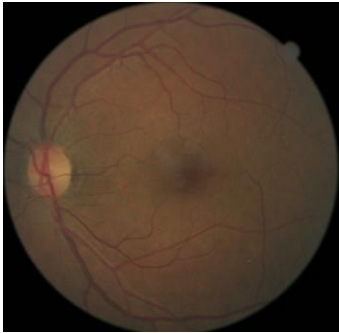6

CSME



7

CSME



Why worry about CSME?

- Leading cause of vision loss in diabetic patients
 - Regardless of insulin-dependence status
 - Regardless of type
 - Regardless of duration

Ferris FL 3rd, Patz A. Macular edema: A complications of diabetic retinopathy. Surv Ophthalmol 1984;28. Suppl:452-61.

8

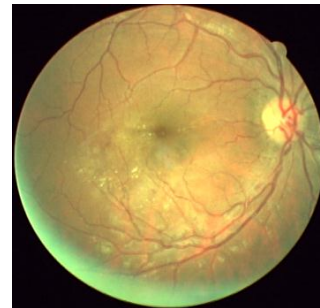9

Mild NPDR

- 38 BF
- DM X 10 years; BS: 100's – 300's
- ❖ History of PDR w/PRP laser '99
- BCVA 20/20- / 20/20-; - Amsler
- DFE . . .

10

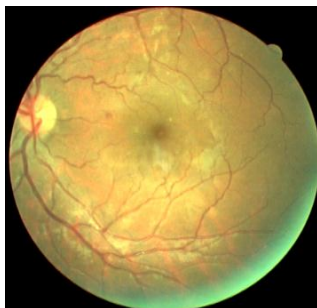Mild NPDR W/O Macular Thickening



OD
H,E w/o thickening
-CSME, - NV

11

Mild NPDR W/O Macular Thickening



OS
H, - CSME, - NV

12

Mild NPDR

- 38 BF
- Assessment and Plan
 - OD: H,E w/o thickening or CSME, - NV
 - OS: H, - CSME, - NV
 - Recheck 4 mo

13

Diabetic Retinopathy - Management Guidelines

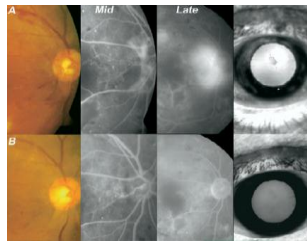
- Moderate NPDR (eg.)
 - W/O macular edema: document and evaluate X 6 mo.
 - W/ macular edema: document, RTC X 4 mo.
 - W/ CSME: document, FA, consider focal laser, evaluate X 2-4 mo.

14

Avastin (intravitreal for PDR)

62.5 ug - 1.25 mg

Regression of INV and NVD 1 week

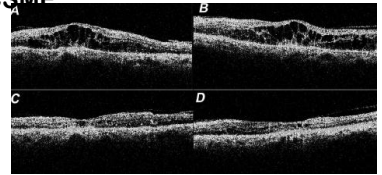


Avery J, et al. Intravitreal Bevacizumab (Avastin) in the Treatment of Proliferative Diabetic Retinopathy. Ophthalmology 2006; 113; 1695.

16

Avastin (intravitreal for PDR)

Regression of INV and NVD @ 6 weeks As well as CSME



Horizontal and vertical representative sections

Avery J, et al. Intravitreal Bevacizumab (Avastin) in the Treatment of Proliferative Diabetic Retinopathy. Ophthalmology 2006; 113; 1695.

17

DRCR Protocol I (Phase 3)

DRCR.net and included n= 691 people (~850 eyes) type I & II DM

- Primary outcome: Change in visual acuity from baseline to 1 year (intent to treat analysis).
- Eyes Randomized: N = 854 (691 Participants)
 - Sham + Prompt Laser (N = 293)
 - Ranibizumab + Prompt Laser (N = 187)
 - Ranibizumab + Deferred Laser (N = 188)
 - Triamcinolone + Prompt Laser (N = 186)

The Diabetic Retinopathy Clinical Research Network. Randomized Trial Evaluating Ranibizumab Plus Prompt or Deferred Laser or Triamcinolone Plus Prompt Laser for Diabetic Macular Edema. Ophthalmology. Jun;117(6):1064-1077.

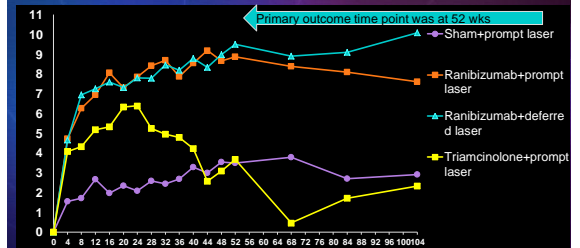
Ophthalmology

DRCR.net group April 2010
On line

slide courtesy D. Schechtman, OD

DRCR Protocol I

Visual acuity



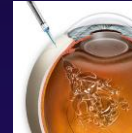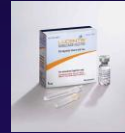The Diabetic Retinopathy Clinical Research Network. Randomized Trial Evaluating Ranibizumab Plus Prompt or Deferred Laser or Triamcinolone Plus Prompt Laser for Diabetic Macular Edema. Ophthalmology. Jun;117(6):1064-1077.

Intraocular Pressure and Cataract Events During 2 Years of Follow-up

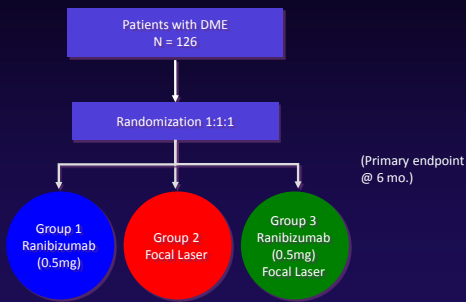
	Sham +Prompt Laser N=293	Ranibizumab +Prompt Laser N=187	Ranibizumab +Deferred Laser N=188	Triamcinolone +Prompt Laser N=186
Elevated Intraocular Pressure/Glaucoma				
Increase ≥ 10 mmHg from baseline	8%	9%	6%	42%
IOP ≥ 30 mmHg	3%	2%	3%	27%
Initiation of IOP-lowering meds at any visit*	5%	5%	3%	28%
Number of eyes meeting ≥ 1 of the above	11%	11%	7%	50%
% of Phakic Eyes that had cataract surgery	12%	12%	13%	55%

READ 2 Study: Ranibizumab for Edema of the mAcula in Diabetes Study Design

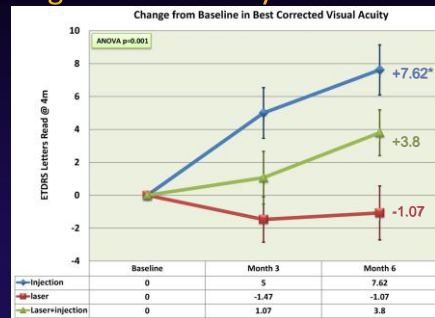
Lucentis
Genentech, San Francisco, CA



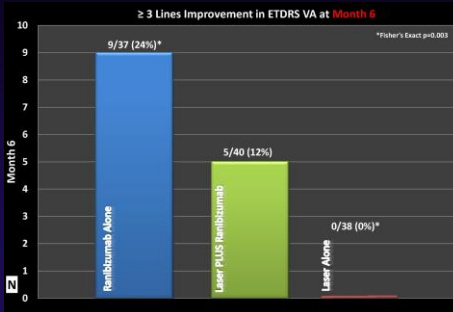
READ 2 Study: Ranibizumab for Edema of the mAcula in Diabetes Study Design



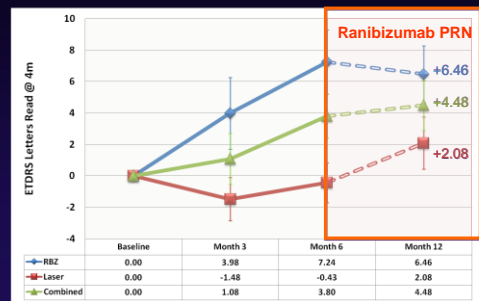
Month 6 - Performance Change in Visual Acuity from Baseline



Month 6 Improvement in Visual Acuity (≥ 3 Lines)



Month 12 Change in Visual Acuity from Baseline



Ranibizumab – Phase 3 RESTORE Study

- Multi-center, randomized, double-masked trial
- 345 Patients were randomized 1:1:1 to
 - ranibizumab 0.5 mg plus sham laser treatment
 - ranibizumab plus active laser treatment
 - sham injection plus active laser treatment
- Three initial injections followed per criteria
 - no improvement over past 2 visits
 - 20/20 VA

Ranibizumab – RESTORE Study

1-year results

	RESTORE			
	Ran n=116	Ran + laser n=118	sham + laser n=111	P value
Mean change in VA at 1 year	6.1	5.9	0.8	<0.0001
Gained 10 letters or more at 1 year	37%	43%	16%	
Gained 15 letters or more at 1 year	22%	23%	8%	
Retinal thickness change (µm)	-119	128	-61	
Mean # of injections	7.0	6.6	7.3	

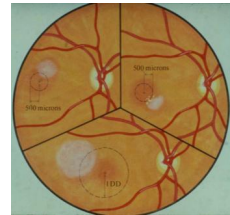
Ranibizumab – Phase 3 RISE and RIDE Preliminary Results

- RISE: at least 15 letters improvement in BCVA with monthly injections at 24 months vs sham.
- Safety consistent with other trials.
- RIDE: 0.3 mg, 0.5 mg, or sham monthly injections. 33% of pts with 0.3 mg and 45% of pts with 0.5 mg gained 15 letters or more in BCVA at 24 months.
- Safety consistent with other trials.

Clinically Significant Macular Edema (CSME)

CSME definitions

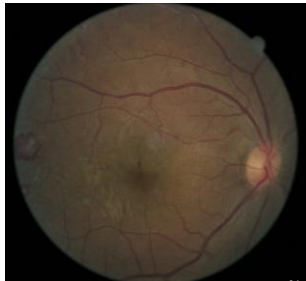- Thickening of the retina \leq 500 microns (1/3 DD) from the center of the macula
- H,E with thickening of the adjacent retina \leq 500 microns (1/3 DD) from the center of the macula
- Any zone of retinal thickening $>$ 1 DA in size \leq 1 DD from the center of the macula



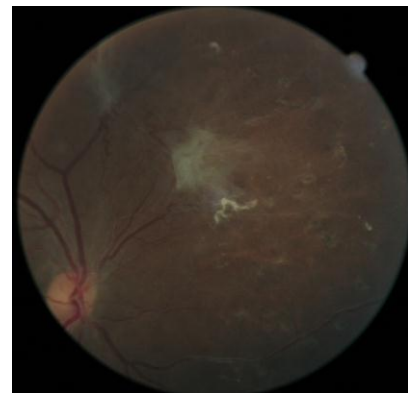30

CASE EXAMPLE

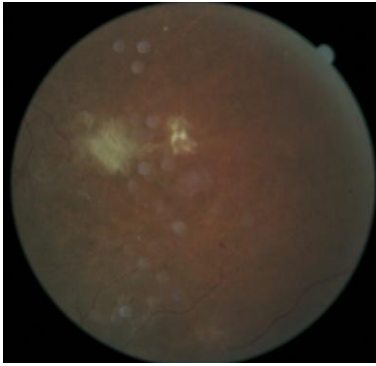
37 BM
30-yr Hx IDDM
S/P PRP
BCVA = 20/15



31

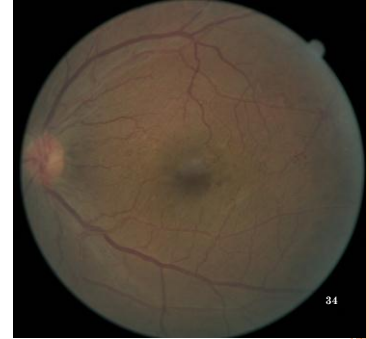

32

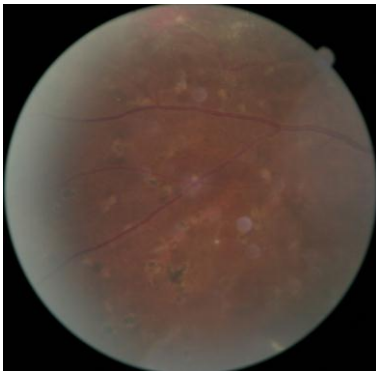


33

OS
37 BM (OS)
BSCVA 20/15

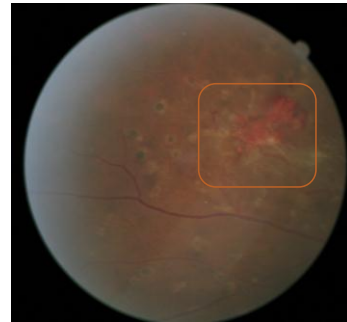


34



35

HOW WOULD YOU MANAGE THIS
PATIENT?



36

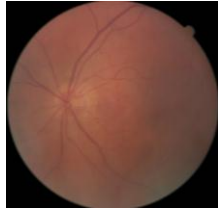
63 W/M

- Ⓒ "When I was grilling on July 4, I noticed sparks and floaters in my left eye."
- Ⓒ "I thought it was time for a CL check, so I came in to see you"
 - Sudden onset
 - No other symptoms
 -

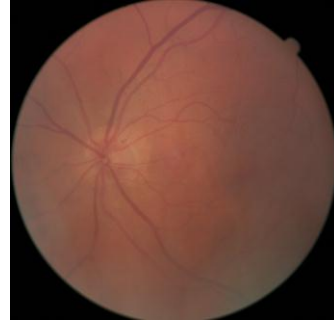37

63 W/M with sparklers

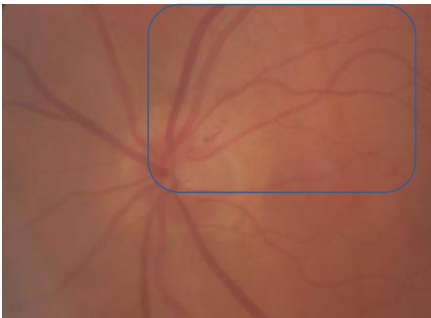
- VA 20/20 in each eye
- Anterior segment evaluation – unremarkable for age
- DFE . . . (OS)



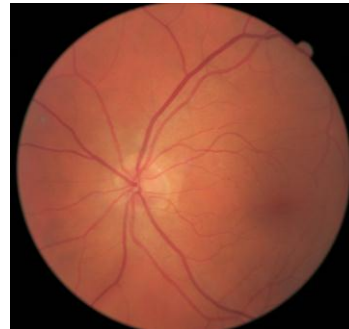
Initial presentation



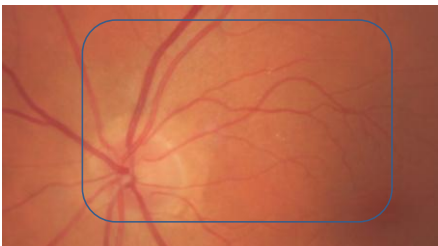
Initial presentation – close-up



Follow-up X 3 weeks



08/14/ 2007



Outcomes

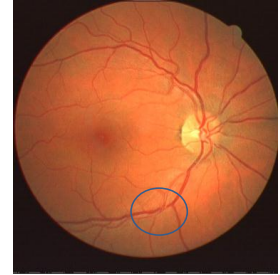- Sent to Internist for evaluation
- Complained of dizziness to Internist
- Carotid Doppler performed
 - Sufficient blockage to recommend carotid endarterectomy
 - Done within 3 weeks of visit to UABSO
 - Successful procedure

- Questions
- Comments

45 F

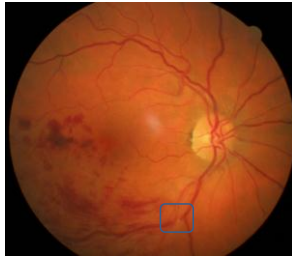- VA = 20/20
- Normal history
- Baseline photo 2000

- Predisposing conditions to retinal vein obstruction?



52 W F

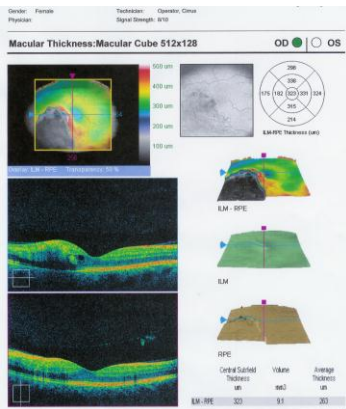
- ☐ Sudden onset of reduced VA (X 7 ½ yrs)
- ☐ 20/80 w/central disturbance
- ☐ What are you going to do?



*Most prevalent coagulation and anti-coagulation disorders in BRVO

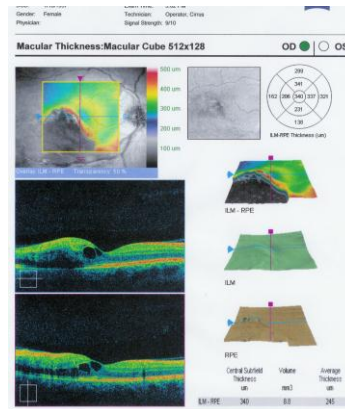
- Resistance to activated protein C (especially factor V Leiden mutation)
- Protein C or protein S deficiency
- Deficiency of antithrombin III
- Genetic mutation in the prothrombin (factor II) gene
- Anti-phospholipid antibodies
- Hyperhomocysteinemia

Rehak J, Rehak M. Branch retinal vein occlusion: pathogenesis, visual prognosis, and treatment modalities. Curr Eye Res. 2008;33:111-31.



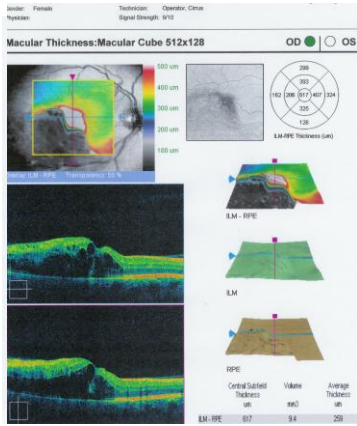
9/ 4/ 2008

Involvement confined to the inner retina

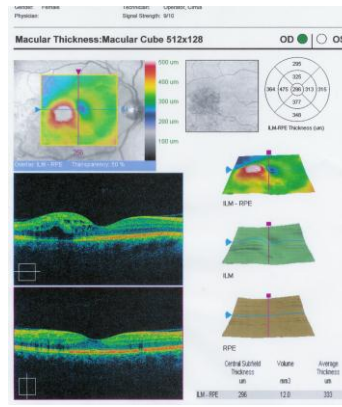


9/ 9/ 2008

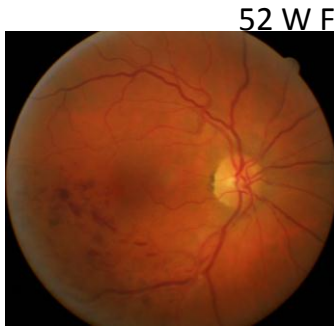Cystoid macular edema; Started on Xibrom (bromfenac) qid



9/ 22/ 2008
 VA 20/200;
 distinct
 macular
 involvement;
 Now what?

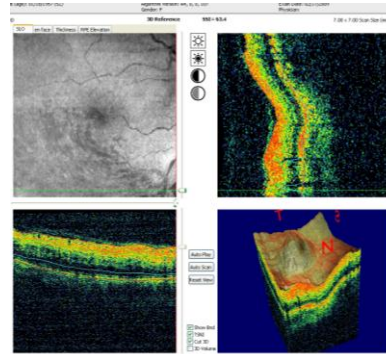


1/ 14/ 2009
 Continued
 on Xibrom
 qid
 Some
 resolution

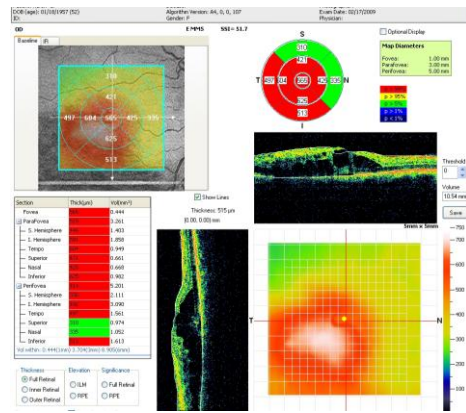
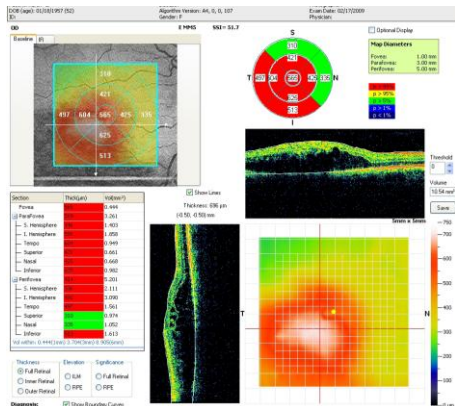


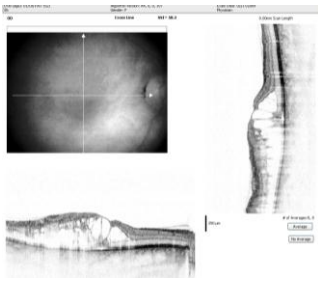
52 W F

1/ 19/ 2009
 Continued
 on Xibrom
 qid



2/ 17/ 2009
 Continued on
 Xibrom qid





2/ 16/ 2009

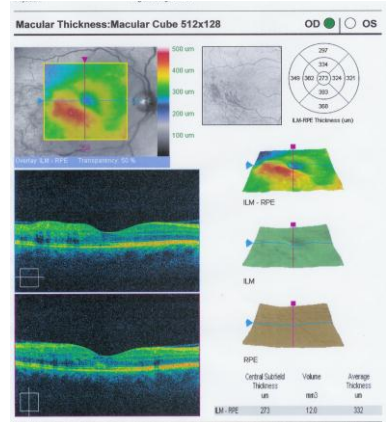
Recommend anti-VEGF intravitreal injection

VF 2/ 24/ 2009

And an Avastin injection

VA = 20/25!!!

Restoration of normal anatomy



***Treatments for ME following RVO**

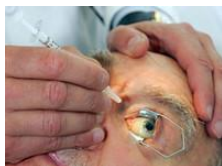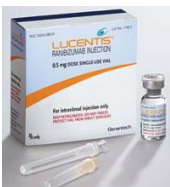- SCORE 5
- CRVO – standard care = observation
- Neither 1 mg nor 4 mg IVTA offered better outcome
- SCORE SRG Arch Ophthalmol 2009; 127; 1101.
- SCORE 6
- BRVO – standard care = grid photocoagulation
- Both 1 mg and 4 mg IVTA showed 15-letter gains in ~ 25% of eyes @ 12 mo.
- Fewer IOP elevations and cataract in the lower dose

***But wait! There’s more!!!**

- CRUISE**
 - CRVO intervention for CME trial 0.3 or 0.5 mg intravitreal ranimuzabab (Lucentis)
 - 46.2 and 47.7 % of eyes gained \geq 15 letters @ 6 mo. (1.1 in the sham group)
- BRAVO**
 - BRVO intervention for CME (same dosing as CRUISE)
 - 55.2 and 61.1% of eyes demonstrated \geq 15 letters @ 6 mo. (1.9 in the sham group)

Retina Congress September 2009 NYC

FDA-approved June 27, 2010

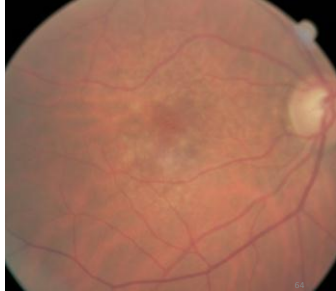

- Questions
- Comments

For the treatment of CME secondary to BRVO/CRVO

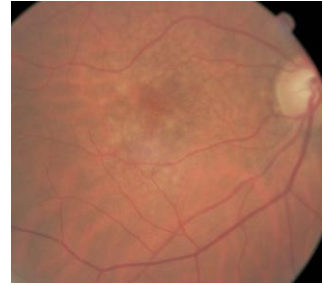AMD progression in a low-risk patient

- 7X W/F
- 20/25 OD
- Baseline



AMD progression in a low-risk patient X 2 years

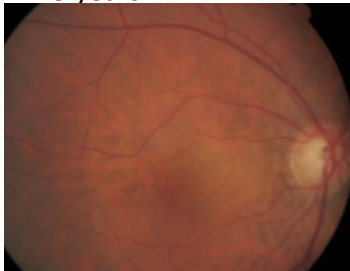
- 7X W/F
- 20/40
- Receives Avastin OD – watch drusen



65

AMD progression in a low-risk patient X 3 years

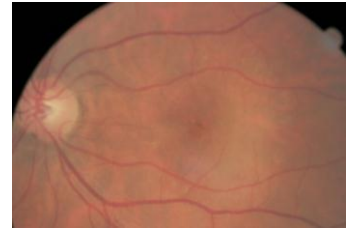
- 7X W/F
- 20/40 OD;
- S/P Avastin
- Note: drusen diminution & beginning GA



66

AMD progression in a low-risk patient

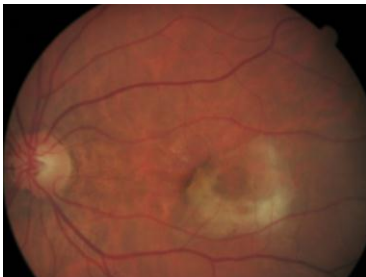
- 7X W/F
- 20/25 OS
- Baseline



67

AMD progression in a low-risk patient

- 7X W/F
- 20/200 OS
- S/P Avastin



69

- Questions
- Comments

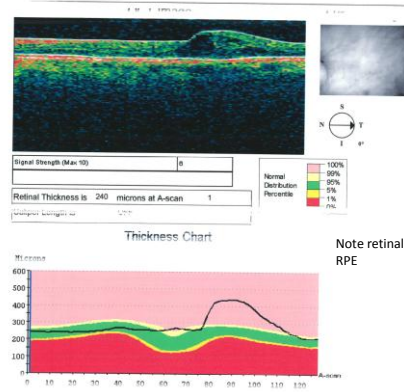
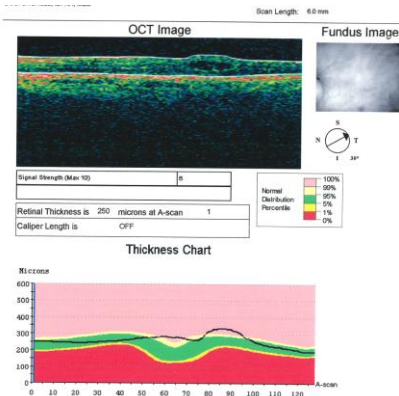
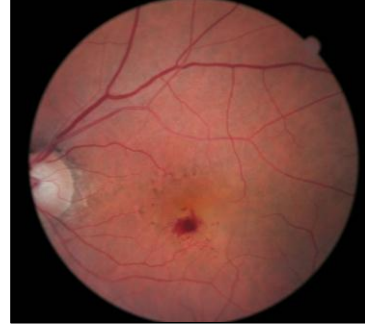70

86 YO

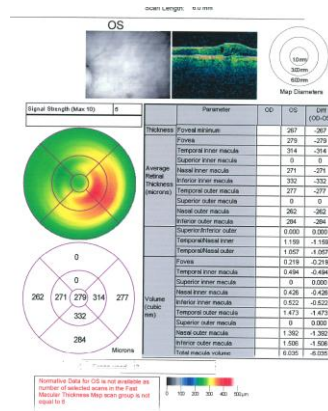
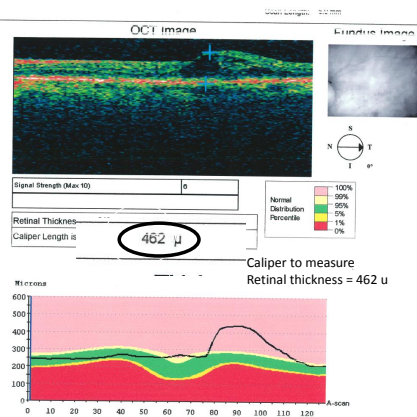
- Presents with reduced VA OS
- POH: repaired peripheral retinal hole SN OS X 11 yrs
- Pseudophakic in each eye
- Medicated for HTn X 20 yrs

20/80

What's the diagnosis and management?



Note retinal thickening with intact RPE



- Questions
- Comments

THANK YOU

